

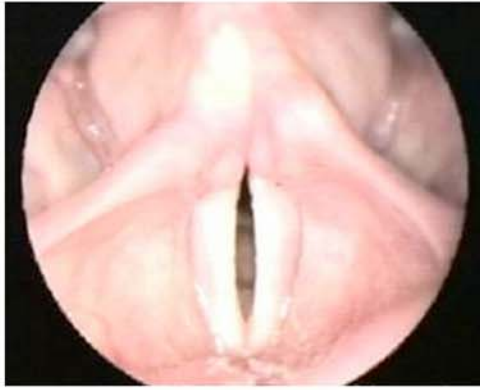

Figure 1: A cardinal prephonation state of the glottis (Esling and Harris 2002).

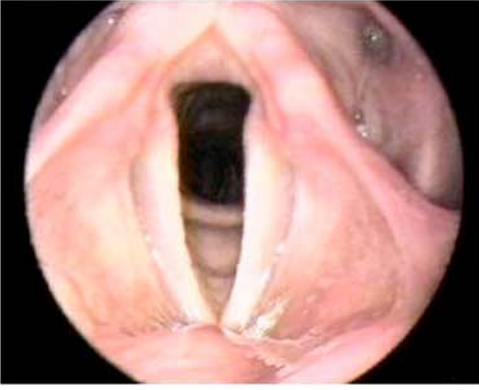

Figure 2: A cardinal breath (voiceless) state of the glottis (Esling and Harris 2002).

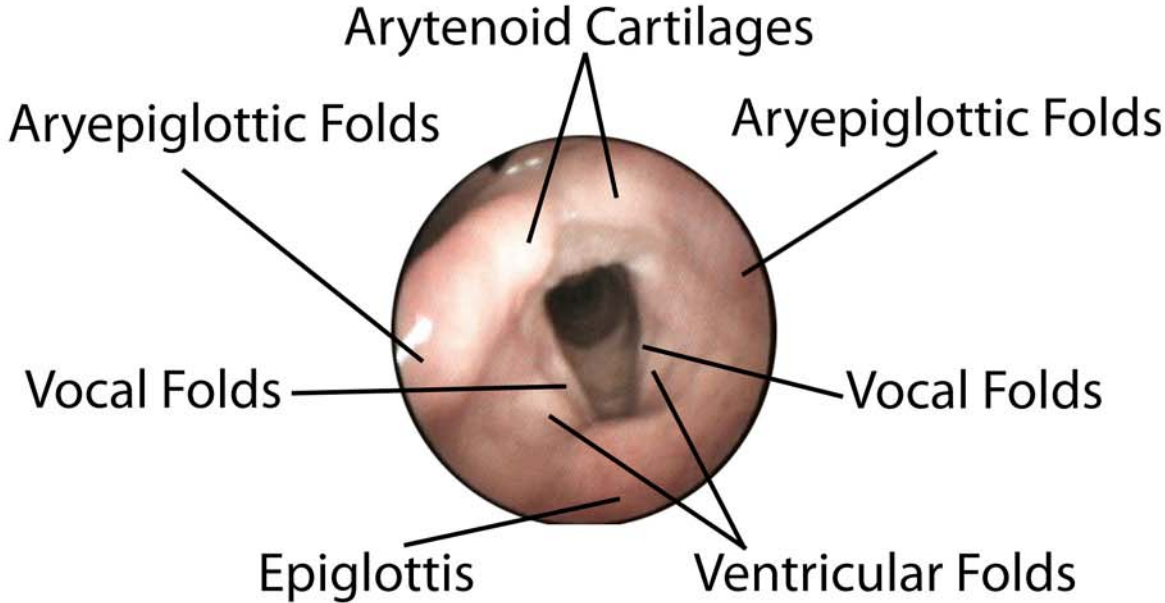


Figure 9: Glottal structures illustrated in a wide-open breath position.